

Hip Resurfacing in Patients Who Have Osteonecrosis and are 25 Years or Under

Siraj A. Sayeed MD, Aaron J. Johnson MD,
D. Alex Stroh BS, Thomas P. Gross MD,
Michael A. Mont MD

Published online: 21 October 2010
© The Association of Bone and Joint Surgeons® 2010

Abstract

Background Young patients with osteonecrosis (ON) treated with THA often have suboptimal function and radiographic failure with eventual revision. Resurfacing may be an option because of potentially increased functionality and decreased radiographic failure, although neither has been confirmed in the literature.

Questions/purposes We therefore compared the clinical scores and radiographic failures of resurfacing patients 25 years or younger with osteonecrosis with those for patients with ON treated with THA.

Methods We identified 17 patients (20 resurfaced hips) who were 25 years or younger and treated by resurfacing for ON. Mean followup was 62 months (range, 32–103 months). This group was matched by gender, age, BMI, and followup to 16 patients (20 hips) treated with THA with a mean 61 month followup (range, 34–88 months). Additionally, the group was compared to 78 patients (87 hips) with ON over age 25 who underwent resurfacing

during the same time with a mean followup of 61 months (range, 27–112 months).

Results The mean Harris score improved from 48 points preoperatively to 93 points with a 100% 7.5 year survivorship in the young resurfacing group. In the THA cohort, the mean score improved from 44 points preoperatively to 94 points postoperatively, with a 93.3% 7.5 year survivorship; similar to the results for all resurfacing patients. Radiographs did not reveal malalignment or progressive radiolucencies in any cohort.

Conclusion At approximately 5 year followup, young resurfacing patients were similar to other resurfacing patients and standard THA patients regarding clinical ratings and radiographic failures.

Level of Evidence Level III, therapeutic study. See Instructions to Authors for a complete description of levels of evidence.

One or more of the authors (MAM, TPG) have received funding from Stryker Orthopaedics, Wright Medical Technologies, or TissueGene. The remaining authors have no disclosures to make. No external funding was received specifically in support of this work. Each author certifies that his or her institution approved the human protocol for this investigation and that all investigations were conducted in conformity with ethical principles of research, and that informed consent for participation in the study was obtained.

S. A. Sayeed, A. J. Johnson, D. A. Stroh, M. A. Mont (✉)
Rubin Institute for Advanced Orthopedics, Center for Joint Preservation and Reconstruction, Sinai Hospital of Baltimore, 2401 West Belvedere Avenue, Baltimore, MD 21215, USA
e-mail: mmont@lifebridgehealth.org; rhondamont@aol.com

T. P. Gross
Midlands Orthopaedics, Columbia, SC, USA

Introduction

Young patients with end-stage hip osteonecrosis (ON) requiring treatment with arthroplasty represent a difficult to treat population, secondary to their medical comorbidities and young age, which often necessitates eventual revision. Primary THA as a treatment for this incapacitating disease accounts for 5% to 10% of all THAs performed in several countries [1, 12, 17]. Several studies suggest THA in patients with ON have revision or clinical and radiographic failure rates ranging from 3% to 48% at a mean followup of 7 to 10 years [20, 24, 36, 38]. High failure rates might be due to patients' underlying conditions (e.g. sickle cell disease, systemic lupus erythematosus, renal transplantation, or excessive alcohol consumption) [2, 21, 26, 33].

However, in recent studies with modern prosthetic designs and surgical techniques, the survival of patients in their late 30's and older range from 93% to 98% at 3 to 10 year mean followup [3, 5, 8, 31].

Patients with end-stage ON tend to be younger and more active than the typical THA population [8, 10, 11, 14, 25]. The durability of conventional THA may not be as good in younger, active patients with hip ON and they may be more difficult to revise [20, 24]. With recent advancements in metal-on-metal (MOM) bearing designs, there have been several reports documenting 93% and greater clinical and radiographic survivorship of resurfacing arthroplasty for the treatment of this disease in patients in their 40's [4, 5, 7, 30, 35], which are comparable to standard THA [17, 29]. Hip resurfacing may be a reasonable treatment option for these younger patients due to its potential low wear rate with preservation of bone stock [30]. Two studies suggest the revision rates of resurfacings are comparable to primary THA [6, 27], from 2% to 5% at a mean of 4 years. Several studies report that gait characteristics more closely resemble those of a normal hip, which may be appealing to younger patients [32, 34, 37].

To determine whether resurfacing is appropriate in patients younger than 25 years suffering from ON, we asked the following: (1) do Harris hip scores of these patients treated with resurfacing compare to those treated with standard THA and those over 25 years with ON treated with resurfacing; (2) is implant survivorship in patients younger than 25 years treated with resurfacing comparable to all patients treated for ON with hip resurfacing arthroplasty; and (3) what percentage of patients younger than 25 years demonstrate radiographic evidence of radiolucencies, penciling, or component malposition?

Patients and Methods

A review of the databases of two surgeons was performed and identified 17 patients (20 hips) 25 years of age or younger with ON who had resurfacing arthroplasty between 2001 and 2007. We compared this cohort to two others: one with 16 patients 25 years old or younger with ON treated with conventional THA performed during the same time, and one with 78 patients aged 26 years and over with ON treated with resurfacing arthroplasty. The indications for both procedures were painful ON with Ficat stage III or higher femoral head lesions of size 30% or greater. We excluded patients who were pregnant, and/or had active human immunodeficiency virus, hepatitis infection, documented allergy to cobalt, chromium, or molybdenum, or a neurologic deficit that might adversely affect gait or weight bearing. Patients who underwent resurfacing came to our institution requesting the

procedure and were assessed for femoral and acetabular bone quality. If they had no preoperative contraindications for resurfacing and there were no large intraoperative femoral neck cysts (greater than 1 cm) or insufficient femoral head remaining, they underwent the procedure. Patients who underwent THA chose that procedure due to personal preference or because their insurance required it.

In the young resurfacing cohort there were nine males and eight females with a mean age of 20 years (range, 11–25 years) and a mean body mass index of 23.2 kg/m² (range, 18.8–36 kg/m²). They were followed for a mean of 62 months (range, 32–103 months). The resurfacing population was matched to the same number of hips in a cohort of patients who underwent standard THA for ON during the same time period. We matched for gender, age, body mass index, and followup (Table 1). For the matched group of 16 patients (20 hips), there were ten males and six females with a mean age of 20 years (range, 13–25 years) and a mean body mass index of 24.4 kg/m² (range, 15.5–40.3 kg/m²). The mean followup was 61 months (range, 34–88 months) (Table 1). The 95% confidence intervals for the demographic factors of both patient cohorts were similar (Table 1). The third cohort consisted of all 78 patients (87 hips) who were treated for ON but over age 25 with MOM hip resurfacing arthroplasty during the same time period. There were 57 men and 21 women with a mean age of 42 years (range, 34–66 years). Their mean body mass index was 27 kg/m² (range, 18–44 kg/m²), and the mean followup was 61 months (range, 27–112 months). In all three patient cohorts, failure was defined as any revision for aseptic purposes. No patients were lost to followup. No patients were recalled specifically for this study. Clinical and demographic data, including but not limited to age, gender, BMI, diagnosis, and Harris hip score were obtained from medical records and radiographs. Institutional review board approval was obtained for the study of these patients from both institutions.

Hip resurfacings were performed by the senior authors using an anterolateral approach (MAM) or a posterior approach (TPG). The Conserve Plus hip resurfacing system (Wright Medical Technologies, Arlington, Virginia) was used exclusively by one senior author (MAM) and the Corin Cormet 2000 hip resurfacing implant system (Corin Group, Cirencester, Gloucestershire, UK) was used by the other senior (TPG). Standard instrumentation for both systems was used for all patients in this study. Acetabular cups (sizes, 44–56 mm) were inserted in a press-fit manner after under-reaming by 1 mm, and all femoral components (sizes, 38–50 mm) were cemented. For the Cormet 2000 hip, cement filled the metal prosthesis in a liquid state to allow for a thin mantle and a more press-fit interposition. For the Conserve Plus, cement was applied in a doughy

Table 1. Demographic and clinical data

Data	MOM THR patients (hips)	Standard THA patients (hips)	Standard THA patients (hips)
Gender			
Male (hips)	9 (10)	10 (11)	57 (64)
Female (hips)	8 (10)	6 (9)	21 (23)
Associated etiologic factors			
Systemic lupus erythematosus	5 (6)	3 (5)	N/A
Sickle cell disease	0	5 (6)	
Neoplasm/chemotherapy	4 (5)	2 (3)	
Trauma	4 (4)	2 (2)	
Legg-calve-perthes	1 (1)	0	
High-dose corticosteroid use	0	2 (2)	
Excessive alcohol consumption	0	1 (1)	
Idiopathic	3 (4)	1 (1)	
Mean age in years (range)	20 (11 to 25) [95% CI: 18 to 21]	20 (13 to 25) [95% CI: 18 to 21]	42 (18 to 66) [95% CI: 40 to 44]
Mean body mass index [kg/m ²] (range)	23.2 (18.8 to 36) [95% CI: 20.86 to 25.54]	24.4 (15.5 to 40.3) [95% CI: 15.5 to 40.3]	27 (18 to 44) [95% CI: 25.93 to 28.07]
Mean followup period in months (range)	62 (32 to 103) [95% CI: 52 to 72]	61 (34 to 88) [95% CI: 53 to 69]	76 (32 to 118) [95% CI: 70 to 82]
Bilateral hip resurfacing (%)	3 (18%)	4 (25%)	9 (12%)
Mean preoperative Harris hip score (range)	48 (12 to 66) [95% CI: 41 to 53]	44 (23 to 72) [95% CI: 36 to 50]	57 (25 to 76) [95% CI: 54 to 60]
Mean postoperative Harris hip score (range)	93 (75 to 100) [95% CI: 89 to 97]	94 (86 to 100) [95% CI: 92 to 96]	88 (51 to 100) [95% CI: 85 to 91]

CI = confidence interval.

state to achieve a 3 mm cement mantle. Standard THA included an uncemented femoral component and acetabular shell with a metal head (Accolade femoral stem with Trident cup, Stryker Orthopaedics, Mahwah, New Jersey) and a cross-linked ultrahigh molecular weight polyethylene liner. Attention was directed at removing superficial collapsed, fibrous bone, or cysts. However, any structurally sound, but nonviable or questionably viable bone was left. Multiple fixation drill holes (10–12 holes) were drilled into all bone areas where cement was applied.

The postoperative rehabilitation regimen for patients was similar. Patients were kept at 20% weight bearing for the first 5 to 6 weeks using crutches or a walker, followed by 50% weight bearing using a cane or crutch in the contralateral hand until 10 weeks, at which time full weight bearing was allowed. Supervised physiotherapy was prescribed at the 5 to 6 week mark until the 10 week mark and focused on gait training and generalized lower extremity strengthening.

Patients returned for postoperative evaluations at 6 weeks, 6 months, 1 year, and annually thereafter. They also returned as needed for any concerns or complications. Further chart review was conducted for any clinical complications, including intraoperative fractures, deep vein thrombosis, or pulmonary embolism during the acute

postoperative period, or any signs of wound irritation or dehiscence. Preoperative and postoperative clinical evaluations for the treatment group and the matched patient cohort were performed by three authors (MAM, QN, TPG) using the Harris hip rating system [19]. The hospital records for all patients were reviewed, including data from preoperative studies, operative reports, and postoperative office visits.

At each clinical visit, radiographic analysis was performed for all patients using standard anteroposterior (AP) and cross table lateral radiographs. Because of the possible variability in the radiographic measurements made by two of the authors (SAS and AJJ), we assessed inter- and intraobserver error in radiographic evaluation before initiating the study of the films of 20 patients. The intraobserver reliability of the two physicians displayed agreement in all of the cases. The interobserver agreement was an exact match in 95% of the cases. To avoid the problem of intra- and interobserver variability in assessing the various demographic parameters, all radiographs were evaluated independently by two authors not involved with the surgery (SAS and AJJ). If there was disagreement, a third author (MAM) interpreted the radiographs until a unanimous decision could be made. Acetabular radiolucencies were evaluated and classified according to the

zones of DeLee and Charnley [13]. The position of the acetabular component was considered optimal if the abduction angle was between 35° and 50° on AP views. For patients with resurfacing arthroplasty, radiolucencies at the bone interface of the femoral component were evaluated using the method described previously [30]. For patients with THA, radiolucencies at the bone interface of the femoral component were evaluated using methods described by Gruen et al. [18] and Engh et al. [15].

Ninety-five percent confidence intervals were calculated for all data reported in this study. Kaplan-Meier survivorship curves [22] were used to evaluate time from surgery to revision and the log-rank test was used to compare survival probabilities between the two groups. The end point of survival was defined as either revision (removal or exchange of one or more components) for any reason or as revision for aseptic loosening. Gender, body mass index, and underlying risk factors leading to end-stage ON were evaluated utilizing a multivariate Cox proportional hazards model to determine their effects on survival outcomes of both patient cohorts. The data was analyzed using GraphPad Prism software (version 5.0; GraphPad Software, San Diego, California).

Results

We observed similar improvements in function for the matched patient cohorts' Harris hip scores, which were similar. The mean preoperative hip score of 48 points (range, 12–66 points) for resurfacing hip arthroplasty and 44 points (range, 23–72 points) for standard THA improved to a mean of 93 points (range, 75–100 points) and 94 points (range, 86–100 points), respectively. After comparing these values, it is clear that there was no difference in the Harris hip scores at last followup between the two groups (Table 1). The mean preoperative Harris hip score in the cohort of all patients with ON treated with MOM hip resurfacing arthroplasty improved from 57 points (range, 25–76 points) to 88 points (range, 51–100 points).

With revision for any reason as the end-point, the Kaplan-Meier survival probability for the two groups under 25 years was similar (log rank statistic: 0.465) (Fig. 1). The 7.5 year survival rate was 100% for the hip resurfacing arthroplasty group and 93.3% for the standard THA cohort (95% confidence interval, 61.3%–99.0%). There was one failure in the standard THA group at 17 months postoperatively, because the patient developed a deep periprosthetic infection. At 24 months after a two-stage revision, the patient remains infection free. In the cohort of all other patients who underwent hip resurfacing for ON, five out of 87 hips (6%) required revision for aseptic

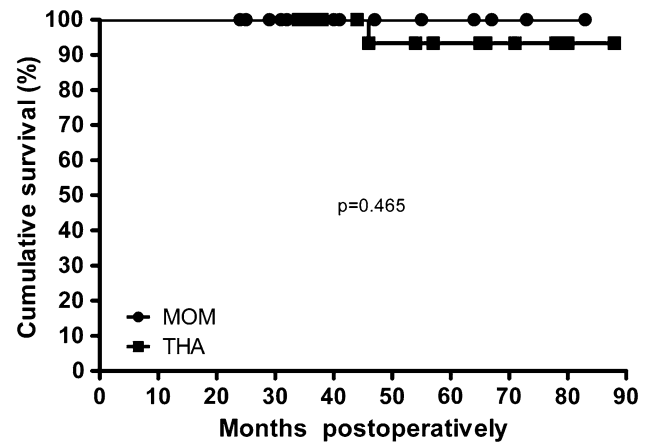


Fig. 1 Kaplan-Meier survivorship curves illustrating similar rates of survival for patients aged 25 years and under with resurfacing compared to standard THA.

reasons. There was no difference (log rank statistic: 0.580) between the 7.5 year survivorship in the under 25 years group with resurfacing and all patients with resurfacing group.

Evaluation of radiographs of the hip resurfacing group did not reveal any component malalignment, radiolucencies, or progressive femoral neck penciling. Additionally, no malalignment of the femoral stem or radiolucencies around the femoral and acetabular components were noted in the standard THA cohort. In the resurfacing and THA groups, the abduction angle of the acetabular component was considered within normal limits (between 35°–50°) in 19 hips (95%) and in 18 hips (90%), respectively. The cups in the remaining resurfaced hip and two standard THA hips were within 5° from this optimal position.

There were no dislocations, nerve palsies, deep vein thromboses, wound complications, or broken hardware in the hip resurfacing and THA cohorts. There were no major discrepancies in leg length in the THA cohort and no fractures of the femoral neck in the hip resurfacing cohort.

Discussion

End-stage ON is a debilitating disease associated with several clinical risk factors. The reported incidence is anywhere from 10,000 to 20,000 new cases per year in the United States [25, 28]. The effects of this disease can be severely debilitating in younger patients. Standard THA may not do so well clinically or radiographically in younger, active patients with hip ON and may be more difficult to revise [20, 24]. With recent advancements in MOM bearing designs, there have been several reports documenting the 93% and greater clinical and radiographic survivorship of resurfacing arthroplasty in patients in their

40's undergoing treatment for this disease [4, 5, 7, 30, 35], which are comparable to standard THA arthroplasty [17, 29]. Hip resurfacing may be a treatment option for these patients due to its potential low wear rate with preservation of bone stock [30]. Therefore, we asked whether prosthetic survival and radiographic failure of resurfacing in younger patients with ON compared to an older group of osteonecrotic resurfacing patients, as well as a group of osteonecrotic patients treated with a standard THA.

There were several limitations to our study. First, the small number of patients may restrict full comparison of the study groups. Although the study has the potential for low power and sampling error, it addresses a very small and specific patient population. The results of this study should only be interpreted for the patient less than 25 years old with hip ON requiring treatment with arthroplasty, and should not be generalized to a more diverse population. Second, it has short minimum followup times of 32, 34, and 27 months in the three cohorts, although the mean followup was approximately 5 years in each cohort. The authors await long-term data on these cohorts to see if these early outcomes are upheld. Third, there were differing etiologies and underlying medical conditions leading to the development of end-stage ON. Since the patient population was small and underlying medical conditions were selective, it was not possible to mitigate this form of bias with matching. Instead, patients receiving resurfacing arthroplasty were compared to patients receiving standard THA without controlling for ON etiology or risk factors. Nevertheless, the 7.5 year clinical survival was similar in all patient cohorts, which appears reliable at an approximately mean followup of 5 years. Even though we found similar results between resurfacing arthroplasty and THA, the effect of metal ions on the placenta during pregnancy is still unclear [9, 39]. As such, caution must be taken when counseling young female patients regarding treatment options. Female patients in our study cohorts received both resurfacing arthroplasty and THA. At the most recent followup, no female patients were pregnant or contemplating having children.

The 7.5 year survivorship in this study cohort is comparable to studies reporting 96% to 98% survivorship at 2 to 11 years in the treatment of ON using THA [16, 23, 31]. One study, of 114 primary THAs (in 101 patients) performed for ON [23] with a mean age of 51 years, reported a 98% survival at a mean of 110 months (range, 84–129 months). Our study compares favorably with the cohort of patients who underwent THA at the senior authors' institutions, as well as the survival rates reported in the literature regarding THA in the treatment of ON. In addition, the difference in the postoperative Harris hip scores in the cohort of patients under 25 years old treated with hip resurfacing versus patients treated with THA were similar (Table 1). Although functional outcomes, survivorship, and radiographic outcomes for hip resurfacing arthroplasty and THA are similar when used for the treatment of ON, there are possible advantages offered by resurfacing a younger patient, such as bone stock preservation. Due to the patients' young age, they are increasingly likely to outlive their prosthesis, and conversion of a well-placed hip resurfacing arthroplasty to a standard THA may be a more attractive alternative than revision of a standard THA.

The 7.5 year survivorship in our patient cohort compares favorably to other reports demonstrating 93% and greater short- and mid-term survivorship of MOM hip resurfacing arthroplasty for hip ON (Table 2). In the longest followup study to date (a mean of 96 months), Amstutz et al. reviewed a series of 70 hips with ON treated with MOM hip resurfacing arthroplasty [4]. The authors reported overall survivorship of 94% at 8 years. Our study supports the findings of MOM resurfacing arthroplasty as a treatment for hip ON. Also, the clinical outcomes we reported with MOM hip resurfacing arthroplasty are similar to other reports demonstrating high clinical performance scores (e.g. Harris hip scores) at short- to mid-term followup for functional improvements in older patients undergoing resurfacing for hip ON [5, 30]. Aulakh et al. [5] and Mont et al. [30] have reported a mean increase in Harris hip scores in patients undergoing resurfacing

Table 2. Comparison of literature

Study	Number of hips	Mean followup (months)	Mean age (years)	Survivorship (%)
Amstutz et al. [3]	70	96	40	94
Aulakh et al. [5]	101	90	42	98
Beaule and Dorey [8]	56	60	41	96
Mont et al. [28]	42	41	42	95
Revell et al. [35]	73	72	43	93
Stulberg et al. [38]	116	20	Not reported	96
Sayeed et al. [current study]	20	62	20	100

arthroplasty for ON of 34 and 39 points, respectively [5, 30]; similar to our patient cohort's mean increase of 45 points.

We found no radiolucencies, penciling, or component malposition. Several previous studies [30, 35] reported nonprogressive lucencies around the femoral and acetabular components that did not affect patient clinical outcomes or survivorship.

In summary, we report an estimated 7.5 year Kaplan-Meier survivorship of 100%, with an average Harris hip score of 93 points, for resurfacing in patients who had a mean age of 20 years and a diagnosis of ON. While we await long-term followup to see if these findings are maintained, we continue to offer this bone-preserving procedure as an alternative to THA for young patients with ON.

Acknowledgment We thank Qais Naziri, MD for outstanding assistance with data collection for this study.

References

- 2005 CJRR Report: Total hip and total knee replacement in Canada. Canadian Institute for Health Information. Available at: http://secure.cihi.ca/cihiweb/products/2005_CJRR_Annual_Report_e.pdf. Accessed December 18, 2009.
- Al-Mousawi F, Malki A, Al-Arabi A, Al-Bagali M, Al-Sadadi A, Booz MM. Total hip replacement in sickle cell disease. *Int Orthop*. 2002;26:157–161.
- Amstutz HC, Grigoris P, Dorey FJ. Evolution and future of surface replacement of the hip. *J Orthop Sci*. 1998;3:169–186.
- Amstutz HC, Le Duff MJ. Hip resurfacing results for osteonecrosis are as good as for other etiologies at 2 to 12 years. *Clin Orthop Relat Res*. 2010;468:375–381.
- Aulakh TS, Rao C, Kuiper JH, Richardson JB. Hip resurfacing and osteonecrosis: results from an independent hip resurfacing register. *Arch Orthop Trauma Surg*. 2010;130:841–845.
- Ball ST, Le Duff MJ, Amstutz HC. Early results of conversion of a failed femoral component in hip resurfacing arthroplasty. *J Bone Joint Surg*. 2007;89:735–741.
- Beaule PE, Amstutz HC, Le Duff M, Dorey F. Surface arthroplasty for osteonecrosis of the hip: hemiresurfacing versus metal-on-metal hybrid resurfacing. *J Arthroplasty*. 2004;19(8 Suppl 3):54–58.
- Beaule PE, Dorey FJ. Survivorship analysis of cementless total hip arthroplasty in younger patients. *J Bone Joint Surg Am*. 2001;83:1590–1591.
- Brodner W, Grohs JG, Bancher-Todesca D, Dorotka R, Meisinger V, Gottsauner-Wolf F, Kotz R. Does the placenta inhibit the passage of chromium and cobalt after metal-on-metal total hip arthroplasty? *J Arthroplasty*. 2004;19(8 Suppl 3):102–106.
- Cabanela ME. Bipolar versus total hip arthroplasty for avascular necrosis of the femoral head. A comparison. *Clin Orthop Relat Res*. 1990;261:59–62.
- Callaghan JJ, Forest EE, Sporer SM, Goetz DD, Johnston RC. Total hip arthroplasty in the young adult. *Clin Orthop Relat Res*. 1997;344:257–262.
- DeFrances CJ, Lucas CA, Buie VC, Golosinskiy A. 2006 National Hospital Discharge Survey. Available at: <http://www.cdc.gov/nchs/data/nhsr/nhsr005.pdf>. Accessed December 18, 2009.
- DeLee JG, Charnley J. Radiological demarcation of cemented sockets in total hip replacement. *Clin Orthop Relat Res*. 1976;121:20–32.
- Dorr LD, Kane TJ, 3rd, Conaty JP. Long-term results of cemented total hip arthroplasty in patients 45 years old or younger. A 16-year follow-up study. *J Arthroplasty*. 1994;9:453–456.
- Engh CA, Massin P, Suthers KE. Roentgenographic assessment of the biologic fixation of porous-surfaced femoral components. *Clin Orthop Relat Res*. 1990;257:107–128.
- Garino JP, Steinberg ME. Total hip arthroplasty in patients with avascular necrosis of the femoral head: a 2- to 10-year follow-up. *Clin Orthop Relat Res*. 1997;334:108–115.
- Graves SE, Davidson D, Ingerson L, Ryan P, Griffith EC, McDermott BF, McElroy HJ, Pratt NL. The Australian Orthopaedic Association National Joint Replacement Registry. *Med J Aust*. 2004;180(5 Suppl):S31–34.
- Gruen TA, McNeice GM, Amstutz HC. “Modes of failure” of cemented stem-type femoral components: a radiographic analysis of loosening. *Clin Orthop Relat Res*. 1979;141:17–27.
- Harris WH. Traumatic arthritis of the hip after dislocation and acetabular fractures: treatment by mold arthroplasty. An end-result study using a new method of result evaluation. *J Bone Joint Surg Am*. 1969;51:737–755.
- Hartley WT, McAuley JP, Culpepper WJ, Engh CA, Jr., Engh CA, Sr. Osteonecrosis of the femoral head treated with cementless total hip arthroplasty. *J Bone Joint Surg Am*. 2000;82:1408–1413.
- Huo MH, Salvati EA, Browne MG, Pellicci PM, Sculco TP, Johanson NA. Primary total hip arthroplasty in systemic lupus erythematosus. *J Arthroplasty*. 1992;7:51–56.
- Kaplan EL, Meier P. Nonparametric estimation from incomplete observations. *J Amer Statist Assn*. 1958;53:457–481.
- Kim YG, Kim SY, Kim SJ, Park BC, Kim PT, Ihn JC. The use of cementless expansion acetabular component and an alumina-polyethylene bearing in total hip arthroplasty for osteonecrosis. *J Bone Joint Surg Br*. 2005;87:776–780.
- Kim YH, Oh JH, Oh SH. Cementless total hip arthroplasty in patients with osteonecrosis of the femoral head. *Clin Orthop Relat Res*. 1995;320:73–84.
- Lieberman JR, Berry DJ, Mont MA, Aaron RK, Callaghan JJ, Rajadhyaksha AD, Urbaniak JR. Osteonecrosis of the hip: management in the 21st century. *Instr Course Lect*. 2003;52:337–355.
- Lieberman JR, Fuchs MD, Haas SB, Garvin KL, Goldstock L, Gupta R, Pellicci PM, Salvati EA. Hip arthroplasty in patients with chronic renal failure. *J Arthroplasty*. 1995;10:191–195.
- McGrath MS, Marker DR, Seyler TM, Ulrich SD, Mont MA. Surface replacement is comparable to primary total hip arthroplasty. *Clin Orthop Relat Res*. 2009;467:94–100.
- Mont MA, Hungerford DS. Non-traumatic avascular necrosis of the femoral head. *J Bone Joint Surg*. 1995;77:459–474.
- Mont MA, Marker DR, Smith JM, Ulrich SD, McGrath MS. Resurfacing is comparable to total hip arthroplasty at short-term follow-up. *Clin Orthop Relat Res*. 2009;467:66–71.
- Mont MA, Seyler TM, Marker DR, Marulanda GA, Delanois RE. Use of metal-on-metal total hip resurfacing for the treatment of osteonecrosis of the femoral head. *J Bone Joint Surg Am*. 2006;88 (Suppl 3):90–97.
- Mont MA, Seyler TM, Plate JF, Delanois RE, Parvizi J. Uncemented total hip arthroplasty in young adults with osteonecrosis of the femoral head: a comparative study. *J Bone Joint Surg Am*. 2006;88 (Suppl 3):104–109.
- Mont MA, Seyler TM, Ragland PS, Starr R, Erhart J, Bhave A. Gait analysis of patients with resurfacing hip arthroplasty

- compared with hip osteoarthritis and standard total hip arthroplasty. *J Arthroplasty*. 2007;22:100–108.
33. Murzic WJ, McCollum DE. Hip arthroplasty for osteonecrosis after renal transplantation. *Clin Orthop Relat Res*. 1994;299:212–219.
 34. Nantel J, Termoz N, Vendittoli PA, Lavigne M, Prince F. Gait patterns after total hip arthroplasty and surface replacement arthroplasty. *Arch Phys Med Rehabil*. 2009;90:463–469.
 35. Revell MP, McBryde CW, Bhatnagar S, Pynsent PB, Treacy RB. Metal-on-metal hip resurfacing in osteonecrosis of the femoral head. *J Bone Joint Surg Am*. 2006;88 (Suppl 3):98–103.
 36. Saito S, Saito M, Nishina T, Ohzono K, Ono K. Long-term results of total hip arthroplasty for osteonecrosis of the femoral head. A comparison with osteoarthritis. *Clin Orthop Relat Res*. 1989;244:198–207.
 37. Shrader MW, Bhowmik-Stoker M, Jacofsky MC, Jacofsky DJ. Gait and stair function in total and resurfacing hip arthroplasty: a pilot study. *Clin Orthop Relat Res*. 2009;467:1476–1484.
 38. Stulberg BN, Singer R, Goldner J, Stulberg J. Uncemented total hip arthroplasty in osteonecrosis: a 2- to 10-year evaluation. *Clin Orthop Relat Res*. 1997;334:116–123.
 39. Ziaee H, Daniel J, Datta AK, Blunt S, McMinn DJ. Transplacental transfer of cobalt and chromium in patients with metal-on-metal hip arthroplasty: a controlled study. *J Bone Joint Surg Br*. 2007;89:301–305.